PIOTR MISIOWIEC*, EDYTA ZOMKOWSKA**,
NATALIA JARMOŁOWICZ-ANIOŁKOWSKA**,
MARIA HORTIS-DZIERZBICKA**

*Department of Neurological Rehabilitation,
Faculty of Medical Sciences University of Warmia and Mazury
**Department of Otorhinolaryngology and Head and Neck Diseases,
Faculty of Medical Sciences University of Warmia and Mazury

https://orcid.org/0000-0003-1138-4647, https://orcid.org/0000-0001-6229-5287
https://orcid.org/0000-0001-6988-7584, https://orcid.org/0000-0003-4333-5890

Instrumental FEES Examination in the Assessment of Swallowing Disorders in Patients with Acute and Subacute Vascular Brain Injury – Advantages and Disadvantages

ABSTRACT

Neurogenic dysphagia, as the most common cause of swallowing disorders in the oral and pharyngeal phase, often leads to potentially fatal clinical consequences such as malnutrition, dehydration, aspiration pneumonia, and also worsens the overall functioning of the patient, including the appearance of depression. Thus early diagnosis of dysphagia and appropriate therapeutic measures are important in preventing the above-mentioned complications. Endoscopic assessment of swallowing disorders using a flexible nasofiberoscope (fiberoptic endoscopic evaluation of swallowing – FEES), together with a videofluoroscopic swallow study (VFSS), are the fundamental instrumental examinations in the evaluation of swallowing disorders in patients with neurogenic dysphagia (1, 2). FESS is currently considered to be the gold standard in the diagnosis of neurogenic dysphagia, because it not only allows direct visualization of the act of swallowing, but is safe for the patient, does not require a contrast agent and does not expose the patient and staff to radiation. However, it has some disadvantages and risks for the patient. The aim of this paper is to present the advantages and disadvantages of the FEES method in the assessment of neurogenic dysphagia, with particular emphasis on patients with acute or subacute vascular brain injury.

Key words: neurogenic dysphagia, acute vascular brain injury, stroke, instrumental diagnostics, screening tests, FEES, VFSS

INTRODUCTION

Neurogenic oropharyngeal dysphagia is a common finding in patients with acute brain injury and, like stroke, often leads to potentially fatal clinical consequences such as malnutrition, dehydration, aspiration pneumonia. It also worsens the overall functioning of the patient, including the appearance of depression. Therefore, an early diagnosis of dysphagia and appropriate therapeutic measures are important in preventing the above-mentioned complications. Endoscopic assessment of swallowing disorders using a flexible nasofiberoscope (FEES), together with a fluoroscopic swallow study (VFSS), are the fundamental instrumental examinations in the evaluation of swallowing disorders in patients with neurogenic dysphagia (1, 2) Widely used in the clinical practice are non-instrumental assessment methods of swallowing disorders based on the patient's or family history, such as the EAT-10 screening questionnaire and screening tests to detect aspiration, e.g. swallowing test, Daniels test, GUSS, allow only to detect indirect symptoms of aspiration, such as cough and change in voice quality (3, 4, 5). The only methods allowing to diagnose the so-called "silent aspirations" are instrumental studies. In the FEES study, after previous functional tests without food, the patient swallows test foods of different consistencies under the control of flexible nasopharyngolaryngoscopy. In the VFSS study, which is a modification of the oesophageal contrast test, under the X-ray vision, the patient swallows radiolabelled test foods with different consistencies. The FEES study, which seems to be the "golden mean" in the diagnosis of neurogenic dysphagia, is a patient-safe study, does not require the administration of a contrast agent, and does not expose the patient and staff to X-rays. However, it has some limitations and risks for the patient. The aim of this study is to present the advantages and disadvantages of FEES in the assessment of neurogenic dysphagia, with particular emphasis on patients with acute or subacute vascular brain injury.

ANATOMOPHYSIOLOGY AND PATHOPHYSIOLOGY OF NEUROGENIC DYSPHAGIA

The act of swallowing consists of three phases: oral, pharyngeal and esophageal. The oral phase, which is dependent on will, is divided into a pre-oral, oral preparatory and oral proper phases. Neurogenic dysphagia, which is caused by nervous system disorders, has a pre-esophageal character, and is called upper dysphagia, associated with the oral and pharyngeal phase of swallowing (6, 7). Because in the act of swallowing both the transversely striated muscles of the mouth, tongue, throat, palate and smooth muscles of the esophagus participate, it requires

the involvement of various structures of the nervous system, such as motor fibers of the cranial nerves (facial, trigeminal, laryngopharyngeal, vagal, and sublingual) whose nuclei are located within the pons and the medulla), sensory fibers of the cranial nerves V, IX, X (sensory innervation area of lips, tongue and throat) and the solitary tract nucleus (involved in the regulation of appetite and perception of taste stimuli). "Central" regulation of swallowing takes place in asymmetric cortical areas (precentral and postcentral gyrus – primary senso-motor cortex), premotor cortex, anterior part of the insula, additional motor cortex, anterior cingulate gyrus and operculum. A very important role in swallowing is played by the extrapyramidal system (subcortical nuclei) and the cerebellum (main role of the left hemisphere and vermis), responsible for coordination, smooth movement and muscle tone (6, 7). Because of such a large diversity of the nervous system structures involved in the swallowing act, there is a large number of acute, chronic and degenerative diseases of the central and peripheral nervous systems in which symptoms of neurogenic dysphagia can be found (8).

The most common cause of neurogenic dysphagia is an acute cerebrovascular injury in the form of a stroke (6, 7, 9–11). In the acute period of stroke, dysphagia occurs in 50%–80% of patients. Aspirational complications occur in 20% of patients. In 90% of patients, dysphagia symptoms recede within 2 weeks of stroke. However, in 8% of patients, dysphagia persists for 6 months or more. That means that for about 70,000 strokes per year in Poland, approximately in 5,600 patients, symptoms of neurogenic dysphagia will remain for at least 6 months. In stroke patients, they will have the clinical symptoms of bulbar or pseudobulbar syndrome. An infrequent consequence of cerebrovascular injury is the clinical syndrome, called *bilateral opercular syndrome* (Foix-Chavany-Marie syndrome), with dysphagia, anartria, apraxia and chewing disorder (12).

FEES ADVANTAGES AND DISADVANTAGES

FESS is currently considered the test of choice in the diagnosis of swallowing disorders, including neurogenic dysphagia (13). It enables the direct visual assessment of the physiology and pathophysiology of specific phases of swallowing, especially the pharyngeal phase.

The advantages of FEES are: simplicity of performance, good tolerance by the patient, possibility of bedside examination, repeating examination in one patient, the ability to assess the movement and sensory components, good assessment of the food content in the lower pharynx (Fig. 1), visualization of aspiration into the airways (Fig. 2 and 3) and relatively low cost.

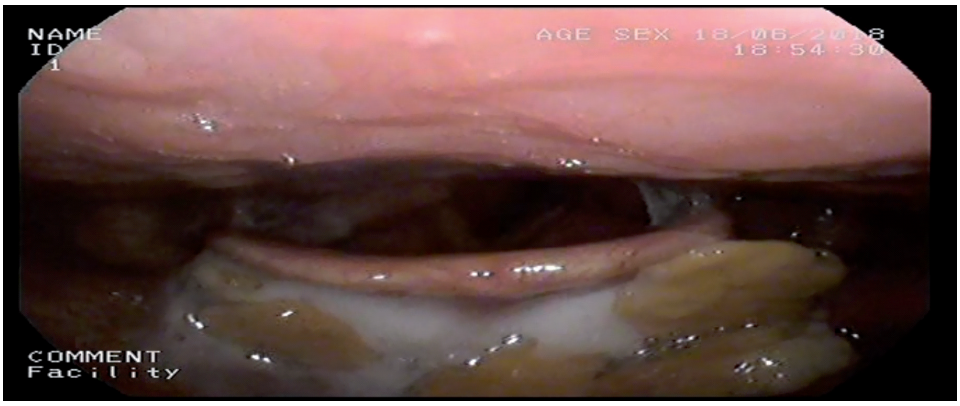

Fig. 1. Retention of food in the hypopharynx
Source: Authors' own study.

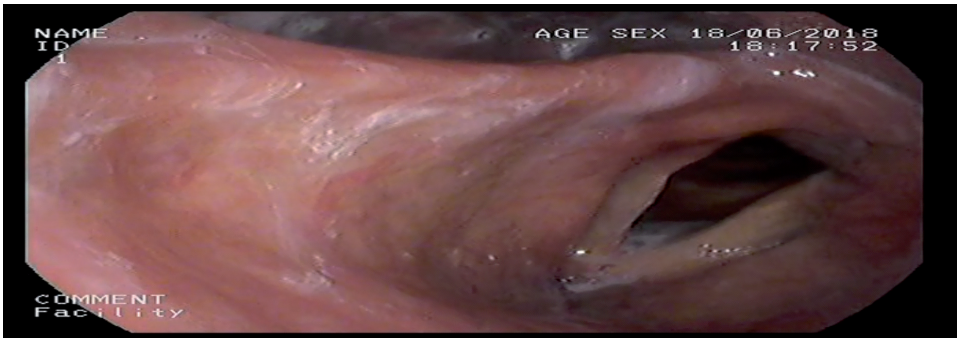

Fig. 2. Aspiration to the respiratory tract
Source: Authors' own study.

Fig. 3. Retention in the hypopharynx and aspiration to the respiratory tract
Source: Authors' own study.

The disadvantages of FEES are the following: the ability to assess only the pharyngeal phase of swallowing, the inability to quantify the aspiration of a given bolus and the so-called *swallowing white-out*, i.e. the inability to assess the first phase of the swallowing act (oropharyngeal preparatory phase), caused by the contact of an endoscope with the base of the tongue, the epiglottis and a food bolus. FEES examination is also a risk and discomfort for the patient, including nausea and/or vomiting, vasovagal syncope, epistaxis, upper airway mucous membrane injury, allergic reactions to the anesthetic and very rare, estimated for 0.03%, having a dramatic course, reflexive laryngospasm (14). We also have to remember about the stress for a patient caused by the test itself. Therefore, before the examination, the patient should be precisely informed about the advantages and disadvantages of FEES, and then the patient or his legal representative should complete the written consent form (15). Sometimes it is difficult, especially for patients with consciousness disorders, aphasia, massive injury of the dominant hemisphere with upper limb paralysis and massive cognitive impairment which very often occur in patients with strokes.

CONCLUSIONS

Currently in Poland, in the period of acute stroke, the assessment of swallowing disorders is predominantly carried out by using the above-mentioned standard questionnaires and screening tests that not allow to accurately assess the retention of food content in the hypopharynx and food aspiration to the airways, including the so-called silent aspiration (Fig. 4).

Fig. 4. Silent aspiration. The patient did not report any problems with swallowing. There was no swallowing disorder in the GUSS test

Source: Authors' own study.

Only a few stroke units in Poland have the possibility of full instrumental assessment of dysphagia using FEES in the acute period of stroke. Despite some disadvantages and some very rare complications, considering the above-mentioned potentially life-threatening complications, it seems that in the near future FEES should be a standard for the early assessment of dysphagia in patients with acute cerebrovascular injury.

REFERENCES

Aviv J.E., Kaplan S.T., Thomson E., Spitzner J., Diamond B., Close L.G., 2000, *The safety of flexible endoscopic evaluation of swallowing with sensory testing (FEESST): An analysis of 500 consecutive evaluations*, "Dysphagia", 15: 39–44 (Pubmed.)

Bakheit A.M., 2001, *Management of neurogenic dysphagia*, "Postgraduate Medical Journal", 77(913): 694–699, indexed in Pubmed: 11677277.

Belafsky P.C., Mouadeb D.A., Rees C.J., Pryor J.C., Postma G.N., Allen J., et al., 2008, *Validity and reliability of the Eating Assessment Tool (EAT-10)*, "The Annals of Otology, Rhinology, and Laryngology", 117(12): 919–924.

Budrewicz S., Słotwiński K., Madetko N., Koszewicz M., 2018, *Zaburzenia połykania w chorobach układu nerwowego – diagnostyka i leczenie*, „Polski Przegląd Neurologiczny", 14(1): 28–34.

Daniels S.K., McAdam C.P., Brailey K., Foundas A.L., 1997, *Clinical assessment of swallowing and prediction of dysphagia severity*, "American Journal of Speech-Language Pathology", 6: 17–24.

De Pippo K.L., Holas M.A., Reding M.J., 1992, *Validation of the 3-oz water swallow test for aspiration following stroke*, "Archives of Neurology", 49(12): 1259–1261.

Foix C., Chavany J.A., Marie J., 1926, *Diplégie facio-linguo-masticatrice d'origine sous-corticale sans paralysie des membres (contribution à l'étude de la localisation des centres de la face du membre supérieur)*, « Revue neurologique », 33: 214–219.

González-Fernández M., Ottenstein L., Atanelov L., et al., 2013, *Dysphagia after stroke: An overview*, "Current Physical Medicine and Rehabilitation Reports", 1(3): 187–196, DOI: 10.1007/s40141-013-0017-y, indexed in Pubmed: 24977109.

Kłęk S., Błażejewska-Hyżorek B., Czernuszenko A., et al., 2017, *Leczenie żywieniowe w neurologii – stanowisko interdyscypilnarnej grupy ekspertów. Część 1. Zasady ustalania wskazań do leczenia żywieniowego*, „Polski Przegląd Neurologiczny", 13(3): 106–119.

Langmore S.E., Pelletier C., Nelson R., 1995, *Results of FEES Survey on Safety of Endoscopy for Swallowing Assessment*. Presented at Fourth Annual Meeting of the Dysphagia Research Society, McLean, VA, October 28.

Langmore S.E., Schatz K., Olsen N., 1988, *Fiberoptic endoscopic examination of swallowing safety: A new procedure*, "Dysfagia", 2(4): 216–219.

Nacci A., Ursino F., La Vela R., Matteucci F., Mallardi V., Fattori B., 2008, *Fiberoptic endoscopic evaluation of swallowing (FEES): Proposal for informed consent*, "Acta Otorhinolaryngologica Italica", 28(4): 206–211.

Simmons K., 1986, *Dysphagia management means diagnosis, exercise, reeducation*, "JAMA", 255(23): 3209–3210, 3212.

Singh S., Hamdy S., 2006, *Dysphagia in stroke patients*, "Postgraduate Medical Journal", 82(968): 383–391, DOI: 10.1136/pgmj.2005.043281, indexed in Pubmed: 16754707.

Trapl M., Enderle P., Nowotny M., Teuschl Y., Matz K., Dachenhausen A., et al., 2007, *Dysphagia bedside screening for acute-stroke patients: The gugging swallowing screen*, "Stroke", 38(11): 2948–2952.

Walshe M., 2014, *Oropharyngeal dysphagia in neurodegenerative disease*, "Journal of Gastroenterology and Hepatology Research", 3(10): 1265–1271, DOI: 10.6051/j. issn.2224-3992.2014.03.408-2.