EWA BOKSA
Jan Kochanowski University in Kielce
Department of Language Communication, Institute of Polish Language
The Polish Association for Persons with Mental Retardation „Koło" in Kielce

Disruption of verbal communication in children and adolescents with congenital *corpus callosum* on the background of communication disorders of persons with mild intellectual disabilities and dyslexia – the report based on own research

SUMMARY

In the article, language communication disorders in children with agenesis or hypoplasia of the *corpus callosum* will be discussed. The functional diagnosis of speech therapy should take into account the fact that the reported symptoms and communication disturbance in patients with damage or hypoplasia of the *corpus callosum* correlate with language disorders on many levels, wherein damage to the right hemisphere of the brain is the basis. The similarity of the symptoms of language disorders in patients with *corpus callosum* defect can also be seen in dyslexia or oligophasia (in persons with mild intellectual disability). Therefore, the process of therapeutic programming needs to involve preparation of speech differential diagnosis based on the most recent neurological, neuropsychological and neurobiological data. The differential diagnosis and treatment program for patients/ students with hypoplastic of CC (*corpus callosum*) is included in the revision of the traditional view of the role of each of the cerebral hemispheres in acquisition and development of language. The author takes the view that in the course of language acquisition first of all cooperation between the hemispheres, the foundation of which is working *corpus callosum*, is of crucial importance.

Key words: communication disorders, *corpus callosum*, agenesis of the *corpus callosum*, hypoplasia of the *corpus callosum*

Agenesis of the corpus callosum (ACC) is a congenital condition, in which the body of the corpus callosum is undeveloped from birth. The corpus callosum

is the largest neural path in the brain, consisting more than 200 million axons, which form the comissure of the right and left hemispheres of the brain. In agenesis of the corpus callosum, this path can be completely or partially impaired.

Since 1992, in Warren S. Brown laboratory at the Institute of Travis (Fuller Graduate School of Psychology) the cognitive and psychosocial researches on psychomotor functioning of patients with agenesis of corpus callosum have been carried out. This project involves persons with ACC of intellectual norm. The research of W. Brown and the team showed that the researched with ACC showed deficits in three areas: neural - related to neuronal conduction between the hemispheres, cognitive, and psychosocial (Brown et al. 2007). It turned out that persons with ACC have difficulty in coordinating hands working with tasks using both hands. They exhibit the problems with transmission of visual information from one hemisphere to the other, and the problems with visual attention when changing the field of vision. Even with the right IQ measured by the Wechsler's scale, there was a discrepancy between the result of intelligence and verbal and spatial tasks, which were at a lower level than in the test without defects of the corpus callosum. It is worth noting that the children and teenagers reached basic skills in language learning (e.g., reading, writing), while results in the methods of solving mathematical tasks were the lowest. The researchers explain that, inter alia, with reduction in speed of information processing between the hemispheres and difficulties in carrying out the problematic tasks.

What is considered the basis for cognitive deficits associated with absence of the corpus callosum affects the problems with explaining and comprehending the meanings of the second order in the language (comprehending proverbs, metaphors, certain forms of humour and irony).

There is no evidence of problems with the memory tasks. However, some difficulties can occur when a task requires complex actions taken for the abstract task.

The results of the research of psychosocial skills, however, showed that persons with ACC often have difficulties with interpretation of the social signals and prediction of the effects of their own actions (Brown et. al. 2007; Paul, Schieffer, Brown 2004).

It can be assumed, therefore, that the above difficulties in individuals with ACC will have an effect on their problems in social communication, opening the research area for speech therapists at the same time.

In order to comprehend the essence of behavioural, social, cognitive and language disorders of persons with ACC, it is worth observing the development and the functions of the neuroanatomical form of the corpus callosum.

STRUCTURE AND FUNCTION OF THE CORPUS CALLOSUM

The *corpus callosum (CC)* is the great commissures next to the anterior and posterior commissure, which combines both the structures of the brain. It is a strip of white matter composed of 200–800 million nerve fibres, making them the largest and fastest way of communication between the opposite sides of the brain. The myelin nerve fibres form the hemispheric white matter: projection – running vertically, comissuring – running laterally and association – running sagittal (Sobolewski 2005: 22).

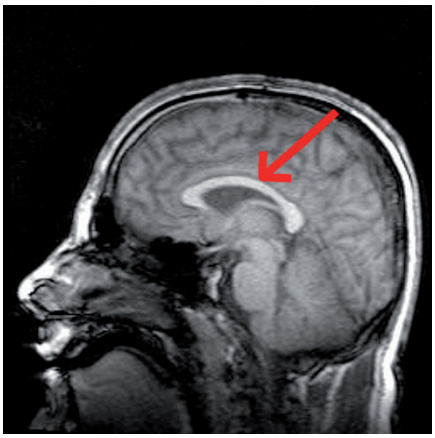

Figure 1. The human brain in the MRI imaging, the sagittal cross-section. A red arrow indicates the corpus callosum. Source: J. Łukaszewicz, 2014

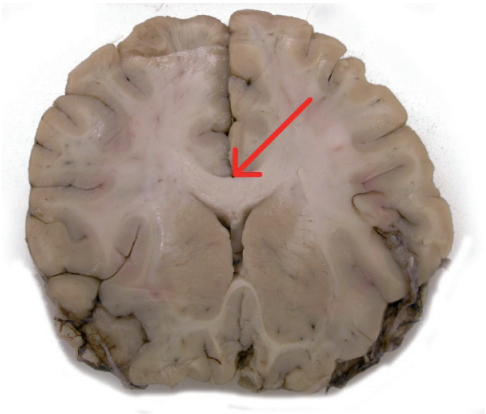

Figure 2. The human brain, the coronal cross-section. A red arrow indicates the corpus callosum. Source: J. Łukaszewicz, 2014

The corpus callosum consists of (from front to rear): panel, trunk, knee, and beak. The fibres of the corpus callosum split up laterally, forming radiance, which consists of head, parietal, temporal and occipital parts. Almost all cortical areas have the connecting fibres, except for representation of the hand in the somatosensory cortex and motor cortex and the whole 17 area – the primary visual area. In this area, the hemispheres comissures cover only the part represented by the binocular visual field, while the remaining parts of this area are not interconnected (Turlejski 2011). Although some parts of the somatosensory cortical visual area and do not receive the connecting fibres, they are received by all associating areas of the parietal and occipital cortex. Each hemisphere has therefore access to information from the opposite half of the body (Nolte 2011: 230). The various parts of the comissure have different functions. The rear part of transfers the visual information, the front part is responsible for transfer of the semantic infor-

mation. The part close to the front involves transfer of the hearing and touching information.

The primary function of the corpus callosum is to coordinate the activities of both cortical hemispheres within:

– Motor control of both hands,
– Ensuring a consistent vision,
– Body awareness,
– Transfer of learning from one hemisphere to the other,
– Cooperation of the hemispheres in solving the complex tasks,
– Development of the sided dominance,
– Social and emotional maturity.

THE DEVELOPMENT OF THE CORPUS CALLOSUM

In the initial period of the embryological development, the telencephalon hemispheres are connected ventrally only within the beak part. On approximately the 14th day of the embryonic development, the axons cross in the midline of the brain in the posterior part. The first axons beyond the centre line of the brain are derived from the bark of the cingulate gyrus, which comes to inter-neuronal communication, enabling simultaneous migration of the numerous nerve fibres and stimulation of the axons journey coming from the nerve cortex. The axons from the cingulate gyrus are the first axons that exceed the centreline of the brain and for this reason, they are called "pioneering". Migration of nerve fibres takes place in conjunction with the glial cells (Kaczan, Śmigiel 2012: 112). The development of the corpus callosum starts in 10th–11th week of the fetal life and progresses into the adulthood. The fastest growth of this structure occurs in the first years of life until the axons myelinate. It doubles its size until the second year of age. At the ageing period, the corpus callosum becomes more efficient and effective (approx. 12 years of age) (Nowak, Ogorzałek 2011: 307; Nowicka 2000, Cieszyńska 2013). Abnormalities of the corpus callosum structure formation take place in the embryonic and fetal life, not later than 9th–20th weeks of gestation, and are caused by improper closure of anterior neural tube (Lemka, Pilarska, Wierzba, Balcerska 2007). This developed corpus callosum can already visualize anatomical MRI at 20th week of gestation (de Laveaucoupet, Bekiesińska-Figatowska, Rutkowska 2011). CC developmental disorders can relate to:

– Inability of axons formation (e.g. in lissencephaly),
– Non-coming and non-directing the axons to the centreline,
– Non-crossing the axons to the other half despite coming to the centreline,

– Turning the axons and form large irregular fibres, the so-called probst bundles forming the medial wall of the lateral ventricles (Blaser, Ilner, Castillo et. al. 2006: 36).

THE CAUSES OF UNDERDEVELOPMENT OF THE CORPUS CALLOSUM

The cause of underdevelopment of the corpus callosum states *inter alia*: fetal exposure to alcohol, such as intrauterine infections. Cytomegalovirus infection, intrauterine error of metabolism, e.g. non-ketotic hyperglycinemia, pyruvate dehydrogenase deficiency, maternal phenylketonuria, Zellweger syndrome (Blaser, Ilner, Castillo et. al. 2006: 36), genetic factors.

According to Blaser, the ACC team accounts for 4% of all CNS malformations (2006).

Disorders of development of the corpus callosum relate to:

Agenesis of the corpus callosum (Lat. *agenesis corporis callosi*) – ACC, AgCC – total lack of the great comissure.

Partial agenesis of the corpus callosum (Lat. *agenesis particularis corporis callosi*) – usually regarding the undeveloped rear part of the CC.

Hypoplasia of the corpus callosum – poorly developed or deformed great comissure. Considering hypoplasia, the CC fibres have the thinner myelin layer or do not have the myelin sheath. Then they conduct the nerve impulses more slowly, which also suggests a slower interhemispheric cooperation.

The clinical signs of developmental disorders of the corpus callosum are (Blaser 2006):

– Seizures,
– Psychomotor retardation,
– Hypertelorism,
– Dysfunction of the pituitary and the hypothalamus,
– Dysfunction in the syndrome of the congenital malformations,
– As isolated dysfunction, often asymptomatic – polemic.

Language disorders in the agenesis of the corpus callosum in persons with intellectual disabilities are subtle and do not give clear symptoms. However, the Polish and foreign literature says that these subtleties in the language skills and the communicative competence level are similar to those with the right hemisphere damage (Daniluk, Borkowska, Kaliszewska 2013; Chiappedi, Fresca 2012).

THE CEREBRAL ORGANIZATION OF THE LANGUAGE FUNCTIONS

In order to comprehend the symptoms of the language and the communication disorders in individuals with ACC and thus plan the treatment, please refer to the cerebral organization of the language functions and follow the views on the matter.

Jagoda Cieszyńska is in favour of the dichotomic functions of the cerebral hemispheres. She focused the therapy of children with different language disorders on the cognitive and the language tasks on the left hemisphere stimulation. According to the author of *Metoda krakowska wobec zaburzeń rozwoju dzieci* [*The Cracow method towards the children's development disorders*] (2007, 2013):

The left hemisphere:

– Receives, identifies and differentiates the speech sounds (temporal-parietal area),

– Works through the material associated with silent reading (visual area),

– Recognize rhymes (temporal area),

– Carries out complex verbal operations (frontal cortex).

The right hemisphere:

– recognizes the nouns in the nominative (heard and read globally),

– Identifies and differentiates phones,

– Controls culturally reading process,

– Controls and allows comprehending the speech prosody (intonation, stress, rhythm),

– Facilitates comprehending of the context of expression,

– Helps in comprehending the meaning of metaphors.

J. Cieszyńska-Rożek stresses, however, that development of language and communication is based on both the left and the right hemispheres tasks. The hemispheric cooperation is based on mutual selectively blocking the activity of one hemisphere over the other. For instance, the left hemisphere is specialized in development of the languageinformation; it blocks its activity in the right hemisphere, which controls operation of the left hemisphere, for example, in processing of spatial stimuli. According to the author, normal stimulation of students with language disorders should involve stimulation of the left hemisphere, so that it can take over the language tasks and free the right hemisphere of the tasks performed linearly (Cieszyńska-Rożek 2013: 42).

M. Klimkowski, A. Herzyk (1987, 1994), A. Herzyk, D. Kądzielawa (1996), G. Krasowicz-Kupis (2012), based on the neuropsychological and the neurobio-

logical research verified the view that in the regulation of language dominates only the left hemisphere, and dominance develops with age. According to the new recognition, we should consider the selective dominance of one of the hemispheres in the regulation of the language functions. In determining the cerebral organization of language, the **hemispheric cooperation** is more important than dominance of the left hemisphere. In addition, they drew attention to the important contribution of the right hemisphere in shaping the brain language processes.

According to M. Pąchalska (2012), if the right hemisphere is damaged, performance and efficiency of communication is disrupted. The skills, relied on integration of the language and the contextual data, are disordered. Pragmatic information processing disorders associated with emotional disorders or space-visual disorders, in turn lead to difficulties in removing the non-language information and disrupts communication.

M. Senderecka (2007), M. Bitniok (2007) and A. Grabowska (2005) are also for correction of existing views. They verify the hypothesis of completely dichotomous division of functions between the two hemispheres, the left one – language, and the right one – visual and spatial. The conclusions of the research can be summarized briefly as follows:

• Development of new techniques for the research of the brain leads to undermining the older views,

• The right hemisphere is not subordinate to the left in all intellectual processes,

• Most of the language tasks activates brain structures bilaterally, with predominance of the left side,

• Cerebral asymmetry is focused on the processes rather than the permanent representations,

• Cooperation between the hemispheres based on their complementarity is assumed,

• The place of the concept of absolute dominance was taken by the concept of complementary specialization of the cerebral hemispheres.

In summary, the right hemisphere plays an important role in the processing of complex language material in activities such as: comprehending and creating discourse, drawing conclusions, integration of information, the use of context, comprehending ambiguous information, metaphorical and emotionally coloured, comprehending jokes, sarcastic speech comprehending. It is important for the so-called theory of mind. Grammatically correct sentence differs from incorrect one. It was proven that persons with impaired development of the corpus callosum have the same language disorders as in patients with the right hemisphere damage (Senderecka 2007). However, the speech therapy practice shows that similar

symptoms interfere with communication in reading and writing can be confused not only in the case of the right hemisphere damage, but also in the case of dyslexia and oligophasia against mild intellectual disability.

OWN RESEARCH

According to the Polish and foreign literature, the corpus callosum defects occur from 3 to 7 cases per 1,000 births, approx. 30–40% of the cases are identified. The other persons in the group of 60% were not examined, due to the seemingly undisturbed psychomotor development (Ciappedi, Bejor 2010; Nowak, Ogorzałek 2011). The author hypothesized that among this 60% group, due to similar symptoms language communication disorders, can lead to erroneous diagnoses posed no neurological analysis of the documentation (in particular, in the case of dyslexia, it is common), according to which the majority of students with clinical symptoms described above diagnosed as persons with developmental dyslexia or as persons with mild intellectual disabilities (the upper limit of normal) or persons with autism spectrum disorders.[1]

The following were covered by the speech and language evaluation: 45 patients: 20 girls and 25 boys between the ages of 10 and 12 years, attending the public schools in Kielce. All persons participating in the study were diagnosed as dyslexic children (30 children), or as a person with mild intellectual disability (15 children).

Methods and tools: Observation, analysis of documents, tasks, which were involved to monitor the communication skills of students involved techniques of reading, reading comprehension, writing, listening, prescription, telling about the text with complex narrative structure (Boksa 2007). Furthermore, the following documents were analysed: the opinions of the psychological and educational centre, the medical documents.

Results:

Five children, two girls and three boys, were found subtle differences at the level of communicative competence and emotional signs indicating:

– Impulsivity, tend to outer relieving of stress,

– Difficulty in scheduled thinking,

[1] Quite interesting research on the differential diagnosis between individuals with ACC and autism spectrum are presented in the article by L. K. Paul, B. Schieffer, B. W. Brown, Social Processing Deficits in Agenesis of the Corpus Callosum: narratives from the Thematic Apperception Test, in: Archives of Clinical Neuropsychology 19, 2004, pp. 215–225. The authors have shown that children with ACC have many behavioural and cognitive problems, especially in the sphere of paying attention, social problems, somatic complaints, mental problems, similar to the problems of children with autism spectrum disorders. However, behavioural disorders are usually less severe than in those with autism and the Asperger's Syndrome. The research confirms the need for a thorough differential diagnosis.

– Low motivation to perform the tasks.

In addition, the researcher attention was drawn by often changes of the conversation without giving any reason, tend to end dialogue and action, digressive speech at the stories and lacks of polite formulas in conversation. These children were reading correctly the new texts. However, they comprehended their content literally. The children spoke with individual sentences, softly, uncertainly. In the course of writing, they formulated simple sentences, forgetting about the principles of correct uppercase letters. In writing comprehension and memory writing, they committed numerous errors in spelling and typing. They did not always point the basic parts of speech. They mastered the ability of abstraction and causal thinking on average level.

The psychological study proved the least developed were: visual perception, eye-hand coordination and visual-motor pace of learning. The graphic-motor skills were reduced. The Bender-Koppitz test showed the indicators specific to organic CNS damage and signs pointing to emotional impulsiveness. The hearing memory proved to be properly developed. The clinical description of the language communication disorders of the researched students required to perform additional neurological research. Therefore, apart from difficulties in learning to read and write, the above-mentioned students had problems with the society learning. By kind permission of the parents, the neurological data verification in the children confirmed hypoplasia of the corpus callosum.

Discussion: The above-mentioned research was not intended as statistical penetration. However, they show that in the process of therapeutic diagnosing, it is important involve quality monitoring and differential diagnosis in relation to those patients, who have similar symptoms of communication disorders, e.g. children with dyslexia, the defects of the corpus callosum, with mild intellectual disabilities. The following part summarizes the language skills of children with defects of the corpus callosum, with dyslexia and intellectual disabilities. The analysis of the performed language tasks showed little discernible difference in the way they perform. These differences are presented in Table 1.

Based on a comparative analysis of oral and written speeches of the children: with dyslexia, mild intellectual disability, as well as in patients with defects of the corpus callosum, it is worth mentioning specific language communication disorders symptoms that indicate damage or hypoplasia of the corpus callosum, and these are:

– Delayed development of speech against the delayed psychomotor development, in most cases,

– Poor ability to assess the society,

– Difficulties in comprehension of facial expressions,

– No sense of humour,

– Difficulties in speech planning,

Tab. 1. Differences in performance of the language tasks for persons with impaired CC, oligophasia (mild intellectual disability) and dyslexia.

Diagnosis Total: 45 persons	Including: persons with defects of the corpus callosum 5 persons	Including: persons with dyslexia 26 persons	Including: persons with mild intellectual disability 14 persons
Reading technique	correct	impaired	impaired
Text comprehension	correct in the literal sense distorted comprehending of metaphor, humour , interpretation of the action as a figure lack of empathy unused context	distortions in the structure of the payload of the text, provision of additional text, development of episodes metaphorical comprehension grows with raising the level of language and metalinguistic competence adequate comprehension of jokes used context	difficulties in comprehending the sequence of events, the multi-theme plot distorted comprehending of metaphor, humour unused context
Reconstructive/ creative writing	correct when copying grapho-motor difficulties. expressions in the form of summaries preserved logical expressions	errors when copying language errors when creating own text preserved logical expressions	numerous language errors when creating own text distorted logical course of expressions
Writing comprehension	numerous spellings, letters, perseveration of syllables and sounds errors	numerous spellings, letters, perseveration of syllables and sounds errors	numerous spellings errors, no uppercase and lowercase letters, diacritics on the end of a sentence metathesis, perseveration

c.d. tab. 1

Social contacts/ pragmatic function of language	emotional lability, poor ability to assess the society, no empathy, low motivation to perform the tasks	correct	excessive exuberance or distance in relation to the speaker, impaired prosody, low motivation to perform the tasks

Description of speech and language disorders in patients with corpus callosum defect corresponds to the information in the Polish and foreign literature (Daniluk, Borkowska, Kaliszewska 2013; Chiappedi, Fresca 2010, 2012; Paul, Brown 2007; Paul, Schieffer, Brown 2004; Brown, Paul, Symington et. al. 2005).

– Difficulties in comprehension of the leading idea in reading and writing,
– Difficulties in comprehension of moral,
– Pragmatic function: low motivation for the language tasks,
– Problems involving extraction of words from the semantic memory,
– Prosody comprehension deficits.

CONCLUSIONS

1. The diagnosis and programming of speech therapy require involving the differential diagnosis of the communication disorders that have similar symptoms of the communication disorders. Extending the diagnosis based on the analysis of **the medical documents and performance of additional neurological research.**

2. Agenesis and hypoplasia of the corpus callosum occur with many diseases and incorporated impairments, but it can also occur as isolated defect in patients with apparently normal psychomotor development.

3. With development of the corpus callosum, interference should be combined with social and pragmatic learning disorders!

BIBLIOGRAPHY

Bitniok M., 2007, *Rola mózgu w procesie językowego porozumiewania się – rehabilitacja logopedyczna w neurologii*, “Logopedia”, 2(5), pp. 4–14.

Blaser S., Ilner A., Castillo M., Hedlund G., Osborn A., 2006, *100 rozpoznań OUN u dzieci*, ed. K. Niezabitowski, Warszawa.

Boksa E., 2007, *Diagnoza i monitorowanie osiągnięć ucznia dyslektycznego polonistycznym testem paralelnym*, [in:] *Zaburzenia komunikacji językowej*, ed. A. Maciejewska, Siedlce.

Brown W., Paul L. K., Symington M., et al., 2005, *Comprehension of humor in primary ACC*, “Neuropsychologia”, 43, pp. 906–916.

Chiappedi M., Fresca A., Baschesis J. M. C., 2012, *Complete Corpus Callosum Agenesis: can it be mild? Case Reports in Pediatrics*, pp. 1–4.

Chiappedi M., Bejor M., 2010, *Corpus callosum agenesis and rehabilitative treatment*, "Italian Journal of Pediatrics", 36, pp. 1–7.

Cieszyńska-Rożek J., 2013, *Metoda krakowska wobec zaburzeń rozwoju dzieci. Z perspektywy fenomenologii i językoznawstwa*, Kraków.

Daniluk B., Borkowska A. R., Kaliszewska A., 2013, *Wybrane aspekty poznania społecznego u pacjenta z pełną agenezją ciała modzelowatego i zespołem Arnolda-Chiari – studium przypadku*, "Psychiatria Polska", XLVII, 3, pp. 519–530.

de Laveaucoupet J., Bekiesińska-Figatowska M., Rutkowska M., 2011, *Co wnosi rezonans magnetyczny do diagnostyki wad wrodzonych mózgu u płodu?*, "Medycyna Wieku Rozwojowego" 3, 2, pp. 376–384.

Harcourt-Webster J., Cir B., Rack J. H., 1965, *Agenesis of the corpus callosum*, "Postgrad. Med. Journal", 41, v.73.

Kaczan T., Śmigiel R., 2012, *Dzieci z wadami ciała modzelowatego- wspieranie rozwoju w pierwszych latach życia*, [in:] *Wczesna interwencja i wspomaganie rozwoju dzieci z chorobami genetycznymi*, Kraków, pp. 112 – 128.

Krasowicz-Kupis G., 2012, *SLI i inne zaburzenia językowe*, Sopot.

Lemka M., Pilarska E., Wierzba J., Balcerska A., 2007, *Agenezja ciała modzelowatego – aspekt kliniczny i genetyczny*, "Annales Academiae Medicae Gedanesis", 37, pp.71–79.

Łukaszewicz J., *Analiza kształtu ciała modzelowatego w obrazowaniu MRI*, lectures by K. Krawiec [in:] www.cs.put.poznan.pl/kkrawiec/wiki/?n=APACS. Algorithms, (access: 13.11.2014).

Nolte J., 2011, *Mózg człowieka. Anatomia czynnościowa mózgowia* v.2, ed. J. Moryś, Wrocław

Nowak K., Ogorzałek A., 2011, *Agenezja ciała modzelowatego* [in:] *Biologiczne uwarunkowania rozwoju i zaburzeń mowy*, ed. M. Michalik, Kraków, pp. 305–317.

Nowicka A., 2000, *Współpraca lewej i prawej półkuli: rola spoideł międzypółkulowych*, "Psychologia – Etologia – Genetyka", 1, pp. 39–60.

Paul L. K, Brown W., et.al., 2007, *Agenesis of the corpus callosum: genetic, developmental and functional aspects of connectivity,* "Nature Reviews Neuroscience", 8, pp. 287–299.

Paul L. K., Schieffer B., Brown W., 2004, *Social Processing Deficits in Agenesis of the Corpus Callosum: narratives from the Thematic Apperception Test*, "Archives of Clinical Neuropsychology", 19, pp. 215–225.

Pąchalska M., 2012, *Neuropsychologia kliniczna. Urazy mózgu*, v. 2, Warszawa.

Senderecka M., 2007, *Różne punkty widzenia prawej i lewej półkuli mózgu*, "Przegląd Psychologiczny", 50(2), pp. 149–164.

Sobolewski P., 2005, *Fizjologia i patologia układu nerwowego. Zagadnienia wybrane* , Sandomierz.

Turlejski K., 2011, *Ewolucja mózgu ssaków*, [in:] *Mózg a zachowanie*, eds. A. Górska, A. Grabowska, J. Zagrodzka, Warszawa, pp. 147–170.